

Healthy gums are the quiet foundation under most confident smiles. They do more than hold teeth in place. They feed bone, cushion chewing forces, and form the biological seal that keeps the mouth's microbial world from slipping into deeper tissues. When gum disease undermines that foundation, teeth loosen or fail, and many people start exploring dental implants. In London, Ontario, where dental practices often collaborate across periodontics, prosthodontics, and oral surgery, implants can restore strength and function remarkably well. The key, and this cannot be overstated, is periodontal health before, during, and after the implant journey.

I have treated patients who came in assuming an implant is a quick fix for a lost tooth. The ones who do best understand that the implant is a team member. The true captain is the surrounding tissue and bone. This article cuts through the marketing gloss to share how we evaluate gum health, plan implants responsibly, and maintain them for the long haul, with practical notes for those seeking dental implants London Ontario wide, comparing alternatives such as dentures London Ontario patients often consider, and where porcelain veneers fit in.

What periodontal health really means for implants

Periodontal health is a clinical and biological state, not just gums that look pink. We assess it with probing depths, bleeding on probing, attachment levels, radiographic bone height, and a careful review of habits that influence inflammation such as smoking and home care. If the tissues are inflamed, even slightly, risk shoots up for post-implant problems like peri-implant mucositis and peri-implantitis.

With natural teeth, the periodontal ligament contains immune cells and blood vessels that help buffer infection and load. Implants integrate directly with bone and lack that ligament. This is why implants are less forgiving of plaque. The soft tissue cuff around an implant has a different architecture, which can be more susceptible to bacterial insult if daily care lapses. I tell patients that implants are strong, but the surrounding biology is sensitive. Respect it, and your implant will likely serve for decades. Ignore it, and even a beautifully placed implant can fail in a few years.

Who makes a good candidate

If you have stable gums, non-smoker status, and good home care, you are already in a favorable category. Many London patients, however, arrive with a history of periodontitis or recent extractions. That is not disqualifying, but it changes the playbook. We invest in stabilization first, then consider implants.

Key indicators we weigh:

- Probing depths and bleeding: deep pockets with frequent bleeding signal ongoing inflammation. We manage these before planning surgery.
- Systemic health: well-controlled diabetes can be fine. Poorly controlled diabetes is not. A recent HbA1c helps. We aim for 7 percent or lower when possible.
- Medications: antiresorptives like oral bisphosphonates can complicate healing. Intravenous forms or previous jaw radiation raise red flags that require specialist coordination.
- Smoking and vaping: both dampen blood supply and raise failure risk. Quitting for at least several weeks pre- and post-op improves outcomes.
- Bruxism: nighttime grinding overloads implants. We plan occlusion conservatively and fabricate protective night guards.

These factors are not checkboxes. They blend into a risk profile that shapes the treatment sequence. One patient might need three months of periodontal therapy and home-care coaching before bone grafting. Another might be ready for a same-day graft and immediate implant because the socket is clean, the gum biotype is thick, and the bite is stable.

Planning with intention in London, Ontario

A strong plan is born from precise information. Most dental implants London providers lean on cone beam CT scans to assess bone volume and density. In my practice, a CBCT is standard for upper back teeth replacements because the maxillary sinus varies person to person. The lower jaw requires vigilance to avoid the inferior alveolar nerve. Digital impressions, facial photographs, and a bite analysis round out the puzzle. We often involve a dental implants periodontist for challenging cases or when patients carry a history of advanced periodontitis.

Beyond anatomy, we plan prosthetics first. Where will the final tooth sit in harmony with your smile and bite? That position dictates ideal implant placement. Surgical guides, designed from the digital plan, help surgeons place implants in a restorative-driven position. Skipping this step can lead to a well-healed implant in a poor spot, which forces compromises like bulky crowns or hard-to-clean contours. Those flaws become plaque traps and drive future inflammation.

Bone and soft tissue: the quiet determinants of success

Many patients arrive with bone loss from periodontitis or from the natural remodeling that follows extraction. In the front of the mouth, only 1 to 2 mm of bone loss can shadow through thin tissue and create a grey hue. In the back upper jaw, the sinus often pneumatizes into the void after a molar is extracted. Think of bone as the scaffold for strength and gum tissue as the curtain for aesthetics and sealing.

Ridge preservation matters. If a tooth must be removed, a socket graft with a membrane frequently preserves ridge shape and volume. Allograft or xenograft materials are common in London, predictable, and avoid a second surgical site. For implants in the esthetic zone, I often perform a connective tissue graft to thicken the gum and stabilize the mucosal margin. It looks like a cosmetic move, but it also protects against recession that can expose implant threads later.

When the sinus floors out, a lateral window sinus augmentation or crestal lift creates room for implant length. It sounds intimidating but, in experienced hands, it is routine, with success rates in the high 90 percent range. The trade-off is healing time. A large lateral lift often needs 6 to 9 months before loading. A minor crestal lift with adequate native bone might allow earlier placement or even simultaneous implant insertion.

Surgical timing and immediate options

There is no single correct timeline. Timing depends on infection control, bone volume, and stability. Broadly, we consider:

- Immediate placement, the day of extraction, if the site is uninfected and we can achieve primary stability. Often paired with a graft to fill the gap and sometimes a temporary crown that stays out of heavy contact.
- Early placement, about 6 to 10 weeks after extraction, once soft tissue has matured but before extensive bone loss. This window often strikes a balance between biology and convenience.
- Delayed placement, 3 to 6 months after extraction when we are managing infection or substantial grafting.

Immediate temporaries in the smile zone can preserve gum architecture if they are meticulously shaped and kept out of function. The risk is that any extra micromovement can disrupt osseointegration. This is where judgment matters. I would rather delay a temporary than jeopardize a clean integration. Patients generally accept an Essix retainer or a bonded temporary for a few months if they understand the stakes.

Prosthetic choices that influence gum health

Cemented crowns on implants have an aesthetic advantage in some cases, but excess cement can trigger peri-implantitis. Screw-retained restorations minimize that risk and simplify maintenance. If we must cement, we use retrievable designs and strict cement control.



Material matters. Monolithic zirconia resists chipping, but it can be abrasive if not polished and glazed properly. Layered porcelain on zirconia produces beautiful translucency for front teeth, yet it carries a slightly higher risk of chipping in heavy biters. The surrounding gum reacts more to surface texture and contours than to the material itself. A crown that is overbulked or impinges on the soft tissue jeopardizes the seal. I would take a less translucent but cleaner emergence profile over a photogenic crown that is impossible to floss.

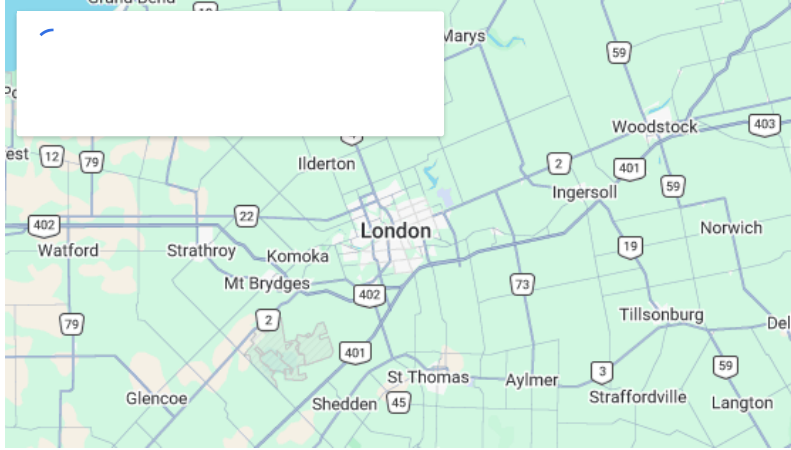
The realities of maintenance

An implant does not grant amnesty from plaque. London's water is moderately hard, and I often see mineral deposits collect on rougher surfaces. Electric toothbrushes with a compact head help access around abutments. Interdental brushes sized correctly to the embrasures are more effective than floss alone for many implant patients. For those with a history of periodontitis, three-month periodontal maintenance visits are prudent for at least the first two years, sometimes for life.

Here is a practical routine that works for most implant patients:

- Brush twice daily for two minutes with a soft brush, focusing on the cuff around the implant crown.
- Clean between teeth and implant surfaces once daily with an interdental brush sized by your hygienist.
- Use a low-abrasive toothpaste and avoid whitening pastes that feel gritty.
- Rinse with an alcohol-free antimicrobial rinse during the first 2 to 3 weeks after surgery, then as advised.
- Wear a night guard if you clench or grind, and bring it to maintenance visits so it can be checked.

Even with diligence, problems can arise. Peri-implant mucositis resembles gingivitis around a natural tooth, and it is reversible with professional debridement and improved home care. Peri-implantitis involves bone loss and often needs surgical intervention. Treatments range from decontaminating the implant surface with ultrasonic tips and air-powder devices, to resective or regenerative surgery, and in severe cases, implant removal and staged reconstruction. The earlier we intervene, the higher the odds of saving the implant.



When dentures or bridges make more sense

Dental implants London candidates often compare options. Full dentures remain the simplest and least costly route for complete tooth loss, but they compromise chewing efficiency and bone volume over time. A middle ground that changes lives is the overdenture retained by two to four implants. In the lower jaw, two implants can stabilize a denture dramatically. In the upper jaw, four implants often allow a palate-free design, improving taste and speech. For some, especially those with medical contraindications to surgery, conventional dentures London Ontario providers make can still serve well with periodic relines and careful hygiene.

Fixed bridges have a place when adjacent teeth already need full crowns and gum contours are stable. They can be planned and completed faster than an implant in some cases. The trade-off is that you must prepare neighboring teeth, and cleaning under a pontic takes discipline. If those abutment teeth are pristine, I prefer an implant to preserve their enamel.

Porcelain veneers solve a different problem. They are not **cosmetic dentistry london ontario** replacements for missing teeth, but they can refine color, shape, and alignment when teeth are intact yet unaesthetic. We sometimes pair a single implant in the back with veneers in the front during a smile redesign. The lesson is to match the tool to the job. Veneers polish the facade. Implants rebuild structure.

Local cadence, costs, and coordination in London

Timelines vary by case complexity. A straightforward single implant, with no grafting, often follows this rhythm:

- Consultation and imaging.
- Surgery with a healing abutment, then 8 to 12 weeks of integration in the lower jaw, 12 to 16 in the upper.
- Impression or scan for the crown.
- Delivery of the final restoration.

Add bone grafting or sinus augmentation, and the timeline stretches to 4 <https://cristiannjxb019.raidersfanteamshop.com/cosmetic-dentistry-in-london-ontario-veneers-bonding-and-beyond> to 9 months. Immediate temporization in the esthetic zone compresses the visible gap time but does not erase biological healing needs.

Costs in London, Ontario, depend on imaging, grafting, sedation, and final materials. As a general orientation in CAD:

- Consultation and CBCT: roughly 150 to 350.
- Single implant placement: about 1,800 to 2,800.
- Abutment and crown: about 1,800 to 2,500.
- Socket preservation graft: 300 to 650.
- Larger ridge augmentation or sinus lift: 1,000 to 3,500 per site.

These are ranges, not quotes, and they shift with the provider, lab, and complexity. Dental insurance may reimburse parts, especially the crown, sometimes a portion of the surgery. Government plans in Ontario generally do not cover implants, so many patients stage treatment or use health spending accounts. For full-arch solutions, costs rise quickly as you add implants, premium materials, and surgical time. It pays to ask how the plan can be sequenced to fit your budget without cutting corners that protect long-term health.

Coordination helps. Many dental implants London practices work closely with a dental implants periodontist for patients with active or historic gum disease. Shared records, joint planning sessions, and local labs speed troubleshooting and keep the plan biologically grounded. Sedation options range from local anesthesia to oral sedation or IV sedation in appropriately equipped offices. If anxiety is high, ask about these early, since scheduling for sedation books out faster.

Complications, and what we do about them

Even good cases carry risk. The most common mechanical issue is a loose retaining screw. You might feel a subtle wiggle or hear a click. It is usually straightforward to retorque or replace the screw, and we examine the bite to reduce lateral forces that prompted the loosening.

Chipping or wear can occur in layered porcelain, especially in grinders. We can polish small chips chairside or replace the crown if needed. Monolithic zirconia reduces chipping risk but must be finished to a high smoothness to be kind to opposing enamel.

Biological complications are more sobering. When a patient with a history of aggressive periodontitis develops peri-implantitis, we move quickly. I have seen a 4 mm crater stabilize with access surgery, decontamination, and bone grafting, then maintain for years. I have also advised removal when the defect shape and implant surface made regeneration unlikely. Starting over, with a staged graft, often beats years of patchwork. That decision weighs frustration tolerance, cost, and the state of the surrounding teeth.

A brief story from the operatory

A teacher in her mid-50s came in after losing an upper lateral incisor to a root fracture. She had moderate chronic periodontitis under control but a thin gum biotype. We stabilized her gums over three months with quadrant cleanings and home-care coaching, then performed a socket preservation graft the day of extraction. Six weeks later, we placed a narrow-diameter implant with high primary stability and a connective tissue graft to thicken the facial tissue. She wore an Essix retainer for three months. The final screw-retained crown blended with her natural central incisors, and three years on, her tissue margin has held. What made the difference was not the brand of implant. It was timing, tissue support, and meticulous hygiene she took pride in maintaining.

When to seek specialist input

If you have generalized bone loss, deep pockets that persist after cleanings, or systemic conditions that slow healing, consult a dental implants periodontist early. They bring a rigor to tissue management and can stage care so the mouth is healthy before hardware is introduced. In multi-tooth gaps, especially in the esthetic zone or near the sinus and nerve, a periodontist or surgeon with extensive implant training reduces surprises.

For patients balancing implants with dentures London Ontario providers can modify, a team approach is vital. A surgeon decides implant positions that enhance stability. A restorative dentist designs the overdenture framework and attachment system. A hygienist teaches how to clean around locator housings or a bar. When the team communicates, complications drop and comfort rises.

Questions worth asking at your consultation

- How is my periodontal health today, and what must improve before surgery?
- What are the grafting needs, materials you recommend, and realistic healing times?
- Will my crown be screw-retained or cemented, and how will you control residual cement?
- What is my personalized maintenance plan, including recall frequency and home tools?
- If complications occur, what is the stepwise plan and estimated costs to manage them?

Bring your priorities to this conversation. Some patients value the fastest path to a front tooth. Others want the sturdiest solution for molar chewing. The best plan reflects what you care about, not just what the scanner suggests.

How porcelain veneers fit alongside implant care

Porcelain veneers enter the picture when form and color need refinement, not structural replacement. If you have small chips, mild crowding, or discoloration that whitening cannot solve, veneers can refresh your smile without altering your bite or requiring surgery. They pair gracefully with implants by aligning shade and character across natural and artificial teeth. The craft lies in coordinating timing. We pick the implant crown shade once soft tissue has matured, then design veneers to match that stable reference. Done in reverse, even a small tissue shift around the implant can create a mismatch.

The materials and finish on veneers matter for periodontal health as well. Overhanging margins and rough transitions trap plaque no less than an ill-contoured implant crown. A veneer that hugs the gumline cleanly and is polished to glass makes daily hygiene easier and supports pink, stippled gums. A well-made veneer does not cause gum disease, but a poorly made one can irritate tissue. The difference is measured in tenths of a millimeter and years of peace of mind.

Final thoughts from the chairside

Implants work beautifully when biology leads and engineering follows. In London, Ontario, we have the tools and teams to deliver that sequence: CBCT planning, ridge preservation, sinus management, and restorative design

that privileges cleanable contours. Yet the quiet hero remains periodontal stability. If you invest first in healthy gums, choose providers who plan restoratively, and commit to meticulous maintenance, implants integrate into your life with little drama.

For some, a well-made denture or a fixed bridge makes more sense. For others, a single implant changes chewing and confidence more than any other dental service. And for many, the best result comes from combining solutions with judgment, such as a two-implant overdenture in the lower jaw or a single implant in the back paired with porcelain veneers in the front. Good dentistry is not a one-size proposition. It is a conversation between your biology, your goals, and a team that respects both.

Paradigm Dental — Business Info (NAP)

Name: Paradigm Dental

Address: 532 Adelaide St N, London, ON N6B 3J4, Canada

Phone: (519) 672-3232

Website: <https://paradigmdental.ca/>

Email: info@paradigmdental.ca

Hours:

Monday: 8:00 AM – 5:00 PM

Friday: 8:00 AM – 3:00 PM

Open-location code (Plus Code): XQV8+3Q London, Ontario

Map/listing URL:

<https://www.google.com/maps/place/Paradigm+Dental/@42.9926997,-81.2356417,17z/data=!4m7!3m6!1s0x882ef3007061d71f:0x772b512bba5c2781.2330668!15sChZQYXJhZGlubSBEZW50YWwgTG9uZG9uWhgiFnBhcmFkaWdtIGRlbnRhbCBsb25kb26SAQ1kZW50YWxfY2xpbnlj4AEA!16s%2Fg%2F>

Embed iframe:

Socials (canonical https URLs):

Facebook: <https://www.facebook.com/61577765603392/>

<https://paradigmdental.ca/>

Paradigm Dental is a family dental clinic in London, Ontario providing general dentistry and a range of in-office dental care services.

Patients can request an appointment for routine exams and cleanings, restorative dental work, and other clinic services listed on the website.

The office address is 532 Adelaide St N, London, ON N6B 3J4, Canada.

To contact Paradigm Dental, call (519) 672-3232 or email info@paradigmdental.ca.

Hours currently listed are Monday 8:00 AM–5:00 PM and Friday 8:00 AM–3:00 PM.

For directions and listing details, use the map listing:
<https://www.google.com/maps/place/Paradigm+Dental/@42.9926997,-81.2356417,17z/data=!4m7!3m6!1s0x882ef3007061d71f:0x772b512bba5c2781.2330668!15sChZQYXJhZGlnbSBEZW50YWwgTG9uZG9uWhgiFnBhcmFkaWdtIGRlbnRhbCBsb25kb26SAQ1kZW50YWxfY2xpbnmlj4AEA!16s%2Fg%2F>

Follow updates on Facebook: <https://www.facebook.com/61577765603392/>

Popular Questions About Paradigm Dental

Where is Paradigm Dental located?

Paradigm Dental is located at 532 Adelaide St N, London, ON N6B 3J4, Canada.

How do I contact Paradigm Dental?

Phone: [+1-519-672-3232](tel:+15196723232)

Email: info@paradigmdental.ca

Website: <https://paradigmdental.ca/>

What are the hours for Paradigm Dental?

Hours listed: Monday 8:00 AM–5:00 PM and Friday 8:00 AM–3:00 PM.

What services does Paradigm Dental offer?

The clinic lists services such as examinations and cleanings, fillings, crowns/bridges, dentures, root canal therapy, orthodontic options, dental implants, and other dental care services (availability can vary).

How do I get directions to Paradigm Dental?

Use the Google Maps listing for turn-by-turn directions:

<https://www.google.com/maps/place/Paradigm+Dental/@42.9926997,-81.2356417,17z/data=!4m7!3m6!1s0x882ef3007061d71f:0x772b512bba5c2781.2330668!15sChZQYXJhZGlnbSBEZW50YWwgTG9uZG9uWhgiFnBhcmFkaWdtIGRlbnRhbCBsb25kb26SAQ1kZW50YWxfY2xpbnmlj4AEA!16s%2Fg%2F>

Landmarks Near London, ON

- 1) [Victoria Park](#)
- 2) [Covent Garden Market](#)
- 3) [Budweiser Gardens](#)
- 4) [Western University](#)
- 5) [Springbank Park](#)