

Dental implants have changed how we restore missing teeth, giving patients the chance to chew comfortably and smile with confidence. For people living with diabetes in London, Ontario, the conversation is more nuanced. Implants can still be a safe, predictable choice, but success depends on thoughtful planning, careful surgery, and consistent follow up. I have placed and maintained implants for many patients with type 1 and type 2 diabetes. The pattern is consistent: when blood sugar is reasonably controlled and oral hygiene is strong, outcomes look a lot like those in non-diabetic patients. When glucose remains high and gum health is unstable, the risk profile shifts.

This article unpacks what really changes for diabetic patients seeking dental implants in London, how to improve safety, the success rates you can realistically expect, and how implants compare with alternatives like dentures. It also covers planning details that matter locally, from referral pathways to payment questions specific to Ontario.

Why diabetes matters for oral surgery and implants

Diabetes affects microcirculation, immune response, and collagen turnover. In plain terms, wounds can heal more slowly, bacteria gain a foothold more easily, and bone metabolism can be altered. All three interact with implant therapy. Osseointegration, the process where bone bonds to a titanium implant, depends on a calm, well nourished, low inflammation environment. When fasting glucose runs high or A1C drifts upward, the surgical site is more prone to infection, the soft tissue can be tender and friable, and bone remodeling can lag.

That is the physiology. In the chair, the signals are practical. I assess whether gums bleed easily on probing, how quickly small abrasions heal, and the consistency of plaque control at home. I ask patients to show me a week or two of glucose logs alongside their most recent A1C. I also look hard at other risk amplifiers like smoking, active periodontal disease, and xerostomia from medications. None of this automatically rules out implants. It simply dictates the tempo and protocols we use.

Safety first: the pre-surgical conversation

For a diabetic patient, the pre-surgical visit <https://juliusvkni046.lowescouponn.com/cosmetic-dentist-or-general-dentist-who-should-you-see> is part dental exam and part medical check-in. The medical team matters here. A quick message to the family physician or endocrinologist can clarify medication timing, bring a borderline A1C down into a safer range, and adjust any anticoagulants if needed. If you use insulin or a GLP-1 agonist, we work out a plan to avoid hypoglycemia during a morning procedure when you will fast.

In London, coordination is usually smooth. Many dental practices have streamlined referral relationships with family health teams. When I contact a physician's office with a one-page summary of the planned procedure, sedation type, anticipated antibiotics, and desired A1C target, I typically get what I need within a few days. This extra step pays dividends because it reduces surprises on surgery day and over the critical first two weeks of healing.

What the evidence says about success rates

Success rates for dental implants are high in general dentistry. Across large cohorts, long-term survival for implants in healthy, non-smoking patients typically lands in the 94 to 98 percent range over five to ten years. Diabetes introduces variability, but the direction of the effect depends heavily on glycemic control.

Here is how I summarize the literature and my own clinical experience:

- Well controlled diabetes, where A1C remains near target and glucose variability is modest, tends to show implant survival that approaches non-diabetic rates. In many series, survival rates in these patients fall somewhere around 92 to 97 percent at five years. Some reports show no statistically significant difference when periodontal health is stable and patients attend maintenance visits.
- Moderately controlled diabetes, often seen with A1C in the high 7s to 8s, carries a small, measurable dip in success, mainly from early healing challenges and a higher chance of peri-implant mucositis evolving into peri-implantitis if plaque control slips.
- Poorly controlled diabetes increases risk. Early failures from infection or lack of osseointegration become more common. Long-term, there is more bone loss and a greater need for intervention. Reported survival in this group can fall into the 80s, sometimes lower when smoking or active gum disease is also present.

There is no magical A1C cutoff that guarantees a result. That said, many implant clinicians prefer to proceed when A1C is in the low to mid 7s or better, assuming no other major risk factors. If someone presents with an A1C of 9 or 10, I typically recommend delaying implant placement, stabilizing gum health, completing any needed extractions or periodontal therapy, and working with the medical team on glucose optimization first. Pushing ahead in that setting is a recipe for disappointments that can be avoided.

Choosing the right plan: staged, immediate, or grafted

Some implant timelines are more forgiving than others. For diabetic patients, I lean toward protocols that respect biology and allow extra healing time.

Immediate implant placement, where a tooth is extracted and an implant is placed the same day, can work in select cases. The benefit is fewer surgeries and a shorter timeline. The trade-off is a tighter margin for error. If the socket is infected or the buccal plate is thin, the implant could be exposed to more inflammatory stress during the most vulnerable window. For diabetic patients, I only consider immediate placement when the site is pristine, bone is ample, and the patient's glycemic control is consistent.

Staged approaches, where we graft first if needed, then place the implant after several months, often yield calmer healing. A common sequence is extraction, thorough debridement, socket preservation with bone graft, four months of healing, then implant placement with another three to four months before restoration. Yes, it is longer. But it spreads risk over time and reduces the chance of a single complication derailing the entire plan.

Full-arch solutions like All-on-X can be successful in diabetics, provided we screen aggressively for periodontal pathogens, manage systemic health carefully, and keep absolute sterility and plaque control top of mind. In my practice, I do not hesitate to stage a full-arch case into an interim denture phase if chronic inflammation has not settled or if A1C is drifting upward. A few extra months reduce the odds of early fixture loss.

Medications, antibiotics, and pain control

Antibiotic stewardship matters. Not every implant needs antibiotics, but for diabetic patients, a short peri-operative course is common. The decision depends on surgical complexity, flap design, grafting, and individual risk. I prefer a narrow-spectrum antibiotic tailored to the expected oral flora and a duration that covers the early healing window without overuse. Pre-op chlorhexidine rinses plus careful mechanical plaque control in the days before surgery lower the bacterial load at the start line.

Pain management should not destabilize glucose. Non-steroidal anti-inflammatory drugs and acetaminophen form the backbone for most patients. Opioids, if used at all, are limited to the shortest possible course. Steroids can help with swelling but are used judiciously, particularly in insulin-dependent diabetics, since they can push glucose higher for 24 to 48 hours. If a steroid is indicated, we plan glucose monitoring around it.

The candidacy assessment: beyond X-rays and models

A volumetric scan like a CBCT helps us measure bone height, width, and sinus or nerve proximity, but it does not tell the whole story. In diabetics, candidacy includes a periodontal baseline. If the same bacteria that cause periodontitis are allowed near the implant, the risk of peri-implantitis grows. I look for bleeding on probing, pocket depths, and the patient's ability and motivation to maintain daily mechanical plaque removal around implant restorations.

I also ask practical questions: Can you return for maintenance every three to four months in the first year? Do you floss or use interdental brushes every day? Do you smoke or vape? Are there dry mouth symptoms from antihypertensives, antidepressants, or antihistamines that make plaque harder to clear? These are not afterthoughts. They predict long-term outcomes as strongly as the ridge width on a scan.

A London, Ontario lens: navigating providers and pathways

The term dental implants London Ontario covers a network of general dentists, prosthodontists, oral surgeons, and periodontists across the city. A dental implants periodontist is often the right first stop for a diabetic patient, particularly if gum disease is present or bone grafting is expected. Periodontists focus on the supporting structures of the teeth and implants, and they are comfortable coordinating care with medical teams.

Many general dentists in London place straightforward implants and collaborate with specialists for complex cases. I encourage patients to ask two simple questions: How many diabetic patients have you treated with implants in the past year, and what maintenance program will you put me on after the crown is placed? You want clear answers to both.

For those comparing options like dentures London Ontario versus implants, most practices can show you models and cases that align with your anatomy, budget, and health profile. A well made denture has its place, especially as an interim solution while stabilizing diabetes or healing grafts. For long-term chewing efficiency and bone preservation, implants usually win when conditions allow.

What success looks like over time

A healthy implant, six months after crown delivery, feels like a natural tooth when you bite. The gum around it looks pale pink and stippled, not red or puffy. There is no bleeding when you clean it, and it does not trap food excessively. On a radiograph, the bone level sits just below the polished collar and remains stable visit to visit. The diary of a diabetic implant patient who does well tends to have the same rhythm: a slightly more deliberate surgery day, an extra day or two of tenderness compared with a non-diabetic peer, and then uneventful follow ups.

Where diabetics sometimes run into trouble is not week one, but month twelve. Life gets busy, hygiene lapses for a stretch, winter colds come through, glucose creeps up during the holidays, and plaque starts to colonize the implant neck. Catch it early, and we reset with a professional cleaning, localized antiseptics, and coaching. Leave it longer, and bone loss can become permanent. The best predictor of smooth sailing is a maintenance routine you can actually live with.

A practical pre-surgery readiness checklist for diabetics

- Recent A1C and a week of glucose logs shared with both dentist and physician
- Periodontal therapy completed and gums stable with minimal bleeding
- Smoking cessation or, at minimum, a solid reduction plan before and after surgery
- Home hygiene tools in place and practiced, including interdental brushes fitted to your spaces
- A clear medication plan for surgery day, including insulin or other glucose-lowering agents

Post-op care that moves the needle

- Keep the site clean with gentle rinsing as directed, usually starting 24 hours after surgery
- Use the prescribed pain and anti-inflammatory plan, and monitor glucose more frequently for a few days
- Stick to a soft diet on the surgical side, and avoid pressure on a temporary tooth if one is present
- Report increasing pain, swelling, or a sweet or foul taste promptly, rather than waiting it out
- Attend the early follow up, even if you feel fine, because early mucosal issues are easiest to correct

Implants vs dentures and other cosmetic restorations

For someone missing a single tooth, a dental implant restores the crown and root analog, preserving bone where the tooth once sat. A traditional bridge can also fill the space, but it requires reshaping the neighboring teeth, which may be perfectly healthy. Porcelain veneers belong to a different category. Veneers beautify front teeth by changing color and shape, but they do not replace missing teeth or restore chewing function. I occasionally use veneers to harmonize a smile around an implant crown, for instance when a dark natural tooth needs brightening to match a new implant crown, but veneers are not a substitute for a missing tooth.

Full dentures remain a practical solution when many teeth are missing, particularly in the short term or when medical conditions make surgery unwise. However, lower full dentures often struggle for stability, and even upper dentures can feel bulky. Two to four implants under a denture can transform comfort and chewing ability. For diabetics who worry about surgery length, a two-implant overdenture is a nice middle path with shorter procedure time and fewer fixtures to heal.

Managing expectations: timelines, touchpoints, and trade-offs

A common London implant timeline for a diabetic patient looks like this. First, a consultation with records, including a CBCT scan. Next, any periodontal therapy and extractions, possibly with socket grafting. Healing for several months. Implant placement in a brief outpatient procedure with local anesthesia, sometimes with mild oral sedation. A healing period of about three to four months. Then an impression or digital scan for the crown, and delivery two to three weeks later. Sprinkle in maintenance visits at three and six months after the crown, then every four to six months thereafter.

The trade-off for this careful sequencing is time. The reward is predictability. Rushing to immediate placement and immediate loading can be tempting, but in a diabetic patient, the margin for error narrows. If speed is essential, we talk frankly about the additional maintenance and monitoring needed.

Costs and coverage in Ontario

Implants are an investment. In London and across Ontario, a single implant tooth often falls in a range that can start around a few thousand Canadian dollars per site and climb with grafting, custom components, and the final crown. A full arch with multiple implants and a fixed bridge is an order of magnitude higher. These are ballpark guides rather than quotes. Material choice, lab partnerships, surgical complexity, and your anatomy all affect the final figure.



Public coverage through OHIP does not extend to implants. Some private dental plans reimburse portions of the surgical placement or the crown, but there are almost always annual or lifetime caps. Seniors who qualify for provincial programs may have access to basic dentures, which can serve as an interim step while saving toward implant stabilization later. Good practices in London will map out phased treatment and provide clear written estimates so you can plan.

A pair of real-world vignettes

A retired teacher with type 2 diabetes, A1C hovering at 7.2, non-smoker, presented with a fractured lower molar. We extracted and grafted the socket, waited four months, placed a single implant, let it heal for three months, and restored it with a screw-retained crown. She returned every four months for maintenance in the first year. Three years later, the peri-implant tissues look textbook clean. She brushes and uses an interdental brush nightly, and she keeps her medical appointments. Her success feels almost boring, which is exactly what you want.

A mid-40s patient with long-standing type 1 diabetes and an A1C in the 8s wanted to move directly to a full-arch fixed solution after losing several upper teeth to periodontal disease. We resisted the urge to go fast. He completed periodontal therapy, switched to a power brush, and tightened glucose control in collaboration with his endocrinologist. We used an interim upper denture for six months while inflammation settled and grafted several sites. Once his A1C dipped into the low 7s and his plaque score improved, we placed four implants and used a converted denture as a temporary while the fixtures osseointegrated. The final bridge has now been in place for two years. He still attends maintenance every four months because his history of periodontitis and diabetes keeps the risk profile elevated, but the radiographs are stable.

How to choose the right clinician in London

Training and judgment are at least as important as technology. Ask about the surgeon's experience with diabetic patients, their protocol for coordinating with physicians, and their thresholds for delaying surgery if glucose is high or gums are inflamed. Clarify whether they use staged approaches when indicated and how they handle maintenance. You also want a restorative partner who thinks long term about cleansability. A beautiful crown that is impossible to floss is a liability for a diabetic patient.

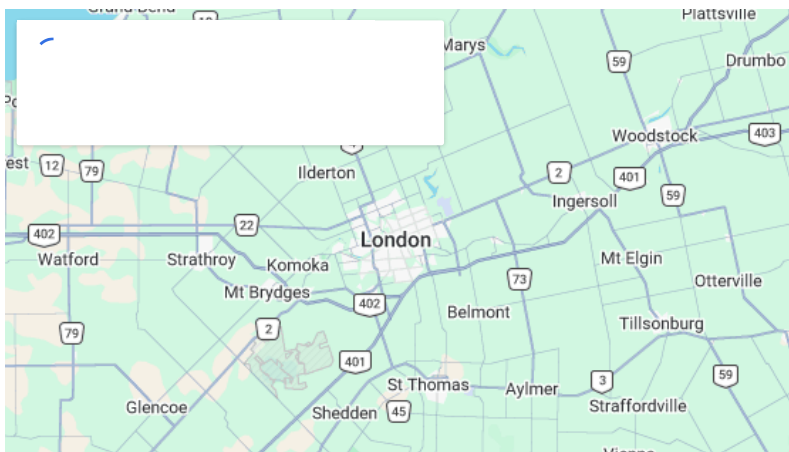
Look for a team that exposes trade-offs without sugarcoating them. If you hear only about speed and none of the biology, keep asking questions. The best outcomes happen when the patient and the team are aligned on a plan that fits health realities, not just wish lists.

Where dentures and implants meet in a plan

I often recommend a high quality denture as a strategic pause. For someone with uncontrolled diabetes and multiple failing teeth, trying to salvage a few questionable roots while planning immediate implants invites complications. Extracting infected teeth, stabilizing health, and wearing a comfortable denture for several months creates a clean slate. Once the A1C improves and the soft tissues look healthy, two to four implants can be placed to stabilize that denture, or we can step up to a fixed bridge if conditions allow. Patients appreciate that they are not locked into one track. A denture can be both a destination and a bridge to implants later.

Final takeaways for diabetic patients considering dental implants in London

Implants are not off limits because you have diabetes. They require respect for biology, careful timing, and disciplined maintenance. In well controlled diabetics with healthy gums and good home care, success rates compare favorably to the general population. The plan that fits you may be a little slower, with extra check-ins and more deliberate hygiene coaching. That is not a compromise. It is how you stack the deck for long-term stability.



Whether you start with a consult for dental implants London or you are comparing options alongside dentures London Ontario, ask for a personalized roadmap. If a front tooth is missing and you are thinking about porcelain veneers to blend adjacent teeth with an implant crown, that can be part of the cosmetic discussion, but it does not replace the functional need for an implant or bridge. Keep the focus on health first, esthetics second, speed last.

If there is one habit that correlates with durable results in diabetic implant patients, it is the maintenance rhythm. Plan on professional cleanings keyed to your risk profile, often every four months at first, then stretching to five

or six months if home care remains excellent and your A1C is stable. Combine that with daily mechanical plaque removal and a clinician who is comfortable treating complex medical patients, and you give your implant every chance to behave like a healthy, natural tooth for years to come.

Paradigm Dental — Business Info (NAP)

Name: Paradigm Dental

Address: 532 Adelaide St N, London, ON N6B 3J4, Canada

Phone: (519) 672-3232

Website: <https://paradigmdental.ca/>

Email: info@paradigmdental.ca

Hours:

Monday: 8:00 AM – 5:00 PM

Friday: 8:00 AM – 3:00 PM

Open-location code (Plus Code): XQV8+3Q London, Ontario

Map/listing URL:

<https://www.google.com/maps/place/Paradigm+Dental/@42.9926997,-81.2356417,17z/data=!4m7!3m6!1s0x882ef3007061d71f:0x772b512bba5c2781.2330668!15sChZQYXJhZGlnbSBEZW50YWwgTG9uZG9uWhgiFnBhcmFkaWdtIGRlbnRhbCBsb25kb26SAQ1kZW50YWxfY2xpbnlj4AEA!16s%2Fg%2F>

Embed iframe:

Socials (canonical https URLs):

Facebook: <https://www.facebook.com/61577765603392/>

<https://paradigmdental.ca/>

Paradigm Dental is a family dental clinic in London, Ontario providing general dentistry and a range of in-office dental care services.

Patients can request an appointment for routine exams and cleanings, restorative dental work, and other clinic services listed on the website.

The office address is 532 Adelaide St N, London, ON N6B 3J4, Canada.

To contact Paradigm Dental, call (519) 672-3232 or email info@paradigmdental.ca.

Hours currently listed are Monday 8:00 AM–5:00 PM and Friday 8:00 AM–3:00 PM.

For directions and listing details, use the map listing:

<https://www.google.com/maps/place/Paradigm+Dental/@42.9926997,-81.2356417,17z/data=!4m7!3m6!1s0x882ef3007061d71f:0x772b512bba5c2781.2330668!15sChZQYXJhZGlnbSBEZW50YWwgTG9uZG9uWhgiFnBhcmFkaWdtIGRlbnRhbCBsb25kb26SAQ1kZW50YWxfY2xpbnlj4AEA!16s%2Fg%2F>

Popular Questions About Paradigm Dental

Where is Paradigm Dental located?

Paradigm Dental is located at 532 Adelaide St N, London, ON N6B 3J4, Canada.

How do I contact Paradigm Dental?

Phone: [+1-519-672-3232](tel:+15196723232)

Email: info@paradigmdental.ca

Website: <https://paradigmdental.ca/>

What are the hours for Paradigm Dental?

Hours listed: Monday 8:00 AM–5:00 PM and Friday 8:00 AM–3:00 PM.

What services does Paradigm Dental offer?

The clinic lists services such as examinations and cleanings, fillings, crowns/bridges, dentures, root canal therapy, orthodontic options, dental implants, and other dental care services (availability can vary).

How do I get directions to Paradigm Dental?

Use the Google Maps listing for turn-by-turn directions:

<https://www.google.com/maps/place/Paradigm+Dental/@42.9926997,-81.2356417,17z/data=!4m7!3m6!1s0x882ef3007061d71f:0x772b512bba5c2781.2330668!15sChZQYXJhZGlnbSBEZW50YWwTG9uZG9uWhgiFnBhcmFkaWdtIGRlbnRhbCBsb25kb26SAQ1kZW50YWxfY2xpbnlj4AEA!16s%2Fg%2F>

Landmarks Near London, ON

- 1) [Victoria Park](#)
- 2) [Covent Garden Market](#)
- 3) [Budweiser Gardens](#)
- 4) [Western University](#)
- 5) [Springbank Park](#)